



**PATIENT**

Drake Keser

**SPECIES**

Canine

**BREED**

Afghan Hound

**SEX**

Male Neutered

**AGE**

10 years

**WEIGHT**

52.5lbs

**INTERPRETED BY**

Maggie Machen  
Lamy, DVM  
DACVIM (Cardiology)

**IMAGING**

**PERFORMED BY**

Pamela Harrigan,  
RDCS

**PRESENTING CLINICAL SIGNS**

History: Recheck echo. History chronic valvular disease - Stage B1. Currently, Drake is doing well. Occasional cough noted. His respirations remain normal. Good appetite and energy. CV/RESP: NSR grade IV-V/VI murmur with PMI left apical area radiating to right with grade II/VI murmur noted on right, PSS, lung fields clear. BP: 150mmHg x 3. On joint supplements. -Pertinent previous echo findings (1/27/21 MML): LA 2.7 cm; LA:Ao 1.0; LV 3.6 cm; normal LA size; mild MR; no TR.

**ELECTROCARDIOGRAPHIC FINDINGS** \*Note: Single lead ECGs are evaluated as a rhythm strip. Morphology/MEA cannot be definitively commented on.

A single lead ECG is available; 25mm/s, 10mm/mV. The average heart rate is 100bpm (range 55-125bpm). The rhythm is sinus in origin, with a p for every QRS complex and vice versa. P and QRS morphologies are positive. 2 isolated VPCs in a one-minute tracing; monomorphic, singles only. No supraventricular ectopic beats, pauses or other dysrhythmias observed. ECG diagnosis: Normal sinus rhythm with isolated VPCs.

**ECHOCARDIOGRAM FINDINGS**

2D, m-mode, color flow and Doppler imaging is available.

**Left ventricle:** The LV diameter is normal with adequate myocardial function. LV wall thicknesses are normal.

**Left atrium:** The left atrium is normal.

**Mitral valve:** The mitral valve is mildly thickened with no prolapse into the left atrial lumen. Mild eccentric mitral regurgitation with a normal velocity.

**Aortic valve/aorta:** The aortic valve is normal in morphology and mobility. Normal aortic outflow velocity; laminar flow. Trivial aortic insufficiency.

**Right ventricle:** Normal right ventricular diameter and morphology indicating no overt evidence of pulmonary arterial hypertension.

**Right atrium:** Normal RA dimension.

**Tricuspid valve:** The tricuspid valve appears normal with trace tricuspid regurgitation.

**Pulmonic valve/pulmonary artery:** The pulmonic valve is normal in morphology and mobility. No pulmonic insufficiency. Normal RVOT velocity; laminar flow.

**Pericardium/other:** No pericardial or pleural effusion noted. No obvious cardiac masses.

**HOSPITAL NAME**

Mass Veterinary  
Specialty Services

**REFERRING VET**

Dr. Masloski

**INVOICE**

20736

**DATE**

8/25/21

**2-Dimensional Measurements**

Ao diam (cm)	2.7
LA diam (cm)	2.9
LA:Ao (Swe)	1.1
IVS thickness (cm)	1.1
LVID diastole (cm)	3.86
PW thickness (cm)	0.9
LVID systole (cm)	2.0
FS (%)	48

**Doppler Measurements**

PV Vmax (m/s)	0.82
AoV Vmax (m/s)	1.7
MR Vmax (m/s)	5.5
TR Vmax (m/s)	NA
TR PG (mmHg)	NA



**PATIENT**

Drake Keser

**SPECIES**

Canine

**BREED**

Afghan Hound

**SEX**

Male Neutered

**AGE**

10 years

**WEIGHT**

52.5lbs

**INTERPRETED BY**

Maggie Machen  
Lamy, DVM  
DACVIM (Cardiology)

**IMAGING**

**PERFORMED BY**

Pamela Harrigan,  
RDMS

**HOSPITAL NAME**

Mass Veterinary  
Specialty Services

**REFERRING VET**

Dr. Masloski

**INVOICE**

20736

**DATE**

8/25/21

**INTERPRETATION OF THE FINDINGS**

Chronic degenerative valve disease persists without evidence of significant progression. The left heart remains normal in dimension with a mild mitral leak. A small tricuspid and aortic leak are noted that were not previously documented; however, the reported blood pressure is reasonable. No additional issues are noted in this study.

The ECG does confirm occasional ventricular premature contractions (VPCs). VPCs are ectopic beats generated from abnormal conductive or fibrotic tissue in the ventricles of the heart muscle, and even frequent single VPCs will often cause no clinical signs in dogs. When sustained however, ventricular tachycardia can lead to symptoms such as lethargy and collapse.

VPCs are a very non-specific finding. They can be primary in origin such as ARVC, be secondary to significant cardiac disease (mild in this study), or be extra-cardiac in origin, i.e., due to pain, stress, inflammation, cancer, GI disease, DIC/sepsis, etc. In this dog with only mild structural disease, all additional causes can be considered. An abdominal ultrasound to monitor for any underlying abnormalities, in addition to full lab work, etc. can be considered. Unfortunately, there is always an elevated risk for collapse and sudden death in any arrhythmic patient, and even on medications this risk unfortunately still persists.

Based strictly on the amount of arrhythmia seen in hospital, low markers of malignancy (such as polymorphism), and a lack of associated clinical signs at home, no anti-arrhythmic treatment is clearly indicated. Monitoring is advised in the future; particularly should any acute lethargy/collapse develop.

Continued assessment of progression in the future will help predict long term prognosis, which remains highly variable at this stage (B1). Serial echoes have showed stable disease which certainly reflects slow progression thus far.

**RECOMMENDATIONS**

- No cardiac medications are clearly indicated.
- Consider full systemic evaluation as discussed
- Fish oil supplementation is recommended for dogs with arrhythmias (1000mg of omega 3 and 6 once to twice daily).
- Monitor at home for collapse, exercise intolerance, and/or lethargy.
- Anesthetic risk is considered mild if needed. Cardiac protective drug choices (opioid/benzodiazepine premedication, propofol or alfaxalone induction, isoflurane gas) are recommended. Pre-oxygenate for 5-10 minutes prior to induction. Monitor for arrhythmias, hypotension, and hypoxia both intra and post-operatively and intervene as necessary. Mild IV fluid restriction is recommended to avoid fluid overload. Avoid heart rate stimulating drugs such as atropine unless clinically indicated.



**PATIENT**

Drake Keser

**PLAN**

- Recommend conservative monitoring with a recheck echocardiogram in 6 months, sooner if any development of clinical signs.

**SPECIES**

Canine

**BREED**

Afghan Hound

**SEX**

Male Neutered

**AGE**

10 years

**WEIGHT**

52.5lbs

**INTERPRETED BY**

Maggie Machen  
Lamy, DVM  
DACVIM (Cardiology)

**IMAGING**

**PERFORMED BY**

Pamela Harrigan,  
RDCS

**HOSPITAL NAME**

Mass Veterinary  
Specialty Services

**REFERRING VET**

Dr. Masloski

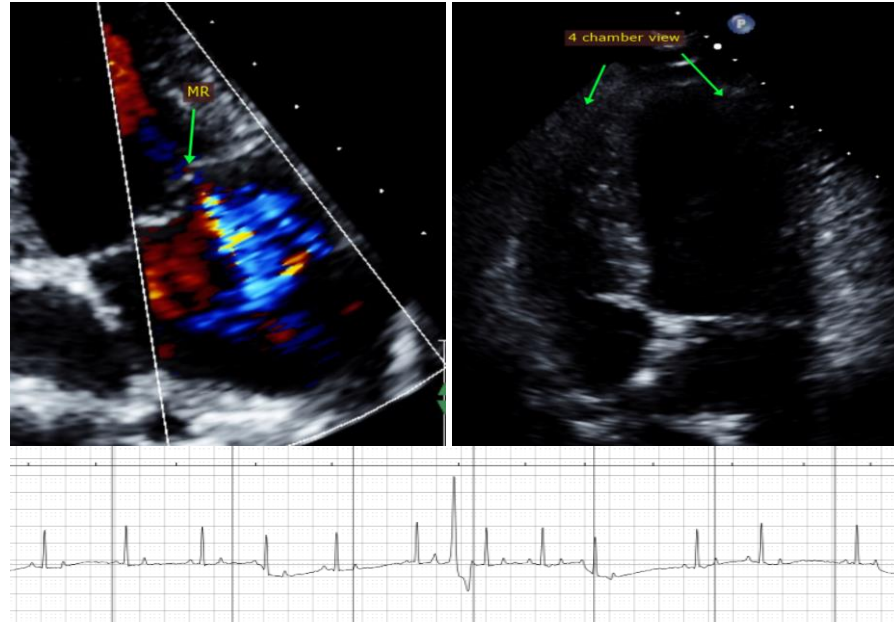
**INVOICE**

20736

**DATE**

8/25/21

**IMAGES**



**The information and recommendations provided are based on the images presented by the referring veterinarian. No evaluation can be communicated regarding pathology that was not visible in the image/video clips provided.**

Thank you for this referral. This report was generated using transcription software, and minor dictation errors may be present. If the clinical or image interpretation does not parallel your findings or if I can be of any further assistance, please contact me.

**Maggie Machen Lamy, DVM**  
**Diplomate of the American College of Veterinary Internal Medicine (Cardiology)**  
info@sonopath.com

**Echocardiogram performed by:** Pamela Harrigan, RDCS  
Pet Animal Ultrasound Service (4paus.com)